

Anaesthesia Management for High-risk Patients: A Case Study of Lower Limb Amputation on Anti-thrombolytic Therapy

PRACHI DESHMUKH¹, VIVEK CHAKOLE²

(CC) BY-NC-ND

ABSTRACT

Anaesthesia is associated with certain risks in patients on anticoagulant therapy, which need to be addressed according to clinical requirements. Regional anaesthesia is linked to venous thromboembolism, with increased chances of haematoma and bleeding risks. Various prophylactic measures are recommended to reduce the risk of postoperative complications for patients on anticoagulants and those with other co-morbidities. Risk assessment of the patient using different tools, such as the Caprini score, along with the type of anaesthetic technique applied, can help achieve better outcomes. Patients with a prolonged history of diabetes present an additional risk. Foot ulcers are a known complication in diabetic patients. Foot ulcerations can lead to various severe effects, such as infection and amputation, which negatively affect the quality of life. Debridement can be a viable option in the care and management of diabetic foot ulcers. Managing thromboprophylaxis in this group can be a major concern due to delayed healing and increased hospital stays. A prolonged anticoagulation regimen further raises the risk of spinal haematoma when undergoing regional anaesthesia, particularly due to the injection needle and catheter insertion. There is a constant rise in the number of patients on prolonged anticoagulants because of the increased incidence of individuals undergoing cardiac and orthopaedic procedures, highlighting the crucial need to address the associated risks. Hereby, the authors present a case of a 65-year-old male who presented with left lower limb gangrene requiring emergency amputation due to sepsis and septic shock, with a history of peripheral vascular disease, diabetes, hypertension, cardiovascular disease, and cardiac bypass surgery for myocardial infarction. Due to his high-risk profile, unilateral spinal anaesthesia (subarachnoid block) was performed using a 27-gauge Quincke needle, which was helpful in mitigating the risk. The procedure was uneventful, with successful haemostasis and good wound recovery.

Keywords: Anaesthesia recovery period, Anticoagulants, Cardiac procedures, Neuromuscular blockade, Preanaesthetic medication

CASE REPORT

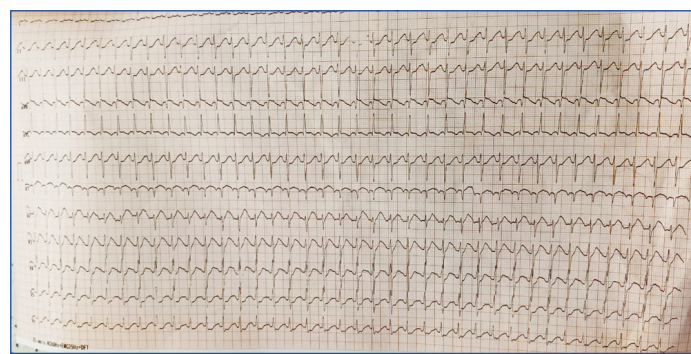
A 65-year-old male presented with left lower limb gangrene accompanied by sepsis and septic shock, which had been diagnosed 10 days prior to the surgery. The patient experienced breathlessness for two days. He had a known history of peripheral vascular disease, diabetes for 15 years, hypertension for 1 year, and left main Coronary Artery Disease with Triple Vessel Disease (CAD: TVD).

He also had a surgical history of Coronary Artery Bypass Grafting (CABG) with the Left Internal Mammary Artery (LIMA) grafted to the Left Anterior Descending artery (LAD), a Saphenous Vein Graft (SVG) to the Obtuse Marginal artery (OM), and another SVG to the Posterior Descending Artery (PDA) six months ago.

His medical regimen included the following medications: Tab. Piperacillin+Tazobactam (2.25 mg, three times daily), Tab. Pantoprazole (40 mg once daily), Tab. Ondansetron (4 mg), Tab. Atorvastatin (20 mg once daily), Tab. Aspirin (150 mg once daily), Tab. Clopidogrel (75 mg once daily), Tab. Glimepiride (2 mg twice daily), and Tab. Telmisartan combined with Clinidipine and Chlorthalidone (40/10/6.25 mg once daily).

The Electrocardiogram (ECG) was altered and suggestive of Inferior Wall Myocardial Infarction (IWMI) at present tertiary care centre [Table/Fig-1]. A 2D echocardiogram showed tachycardia, LAD territory hypokinesia, mild left ventricular dysfunction, trivial mitral regurgitation, and Left Ventricular Ejection Fraction (LVEF) of 45%. The patient was further screened by color Doppler of the left lower limb, which revealed biphasic flow in the left common femoral artery, superficial femoral artery, and deep femoral artery. The left popliteal artery, anterior tibial artery, and posterior tibial artery showed dampened monophasic flow on Doppler. The Doppler results were

suggestive of extensive atherosclerotic calcification in all lower limb arteries, with no evidence of deep vein thrombosis.

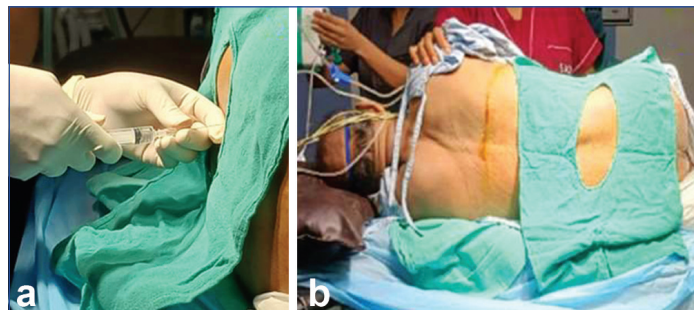

[Table/Fig-1]: The ECG of the patient on admission.

Antiplatelet medications were discontinued five days before surgery. The patient was on anticoagulants, which posed an increased risk for anaesthetic agents and associated procedures. The present case involved a known history of Chronic Obstructive Pulmonary Disease (COPD) with ventilator-associated pneumonia post-CABG, with serial arterial blood gases showing hypoxic changes and metabolic acidosis suggestive of sepsis. The patient was scheduled for above-knee amputation with management of sepsis.

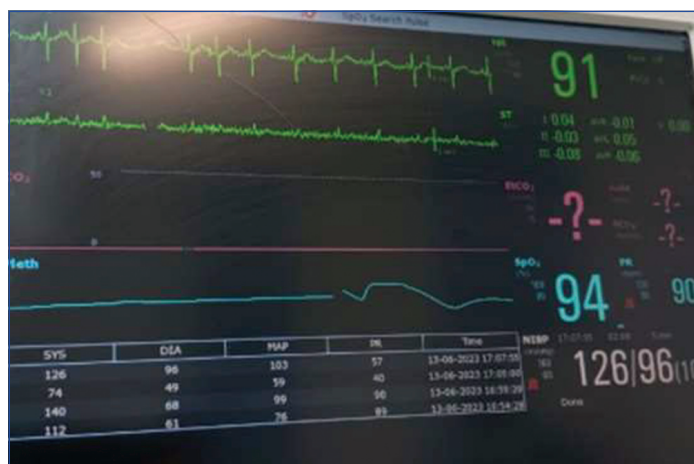A unilateral low-dose subarachnoid block was administered to the patient in the left lateral position at the L3-L4 level in the midline with the help of a 27G Quincke needle. The lateral position was preferred as it provides optimal and even spread of anaesthetic drugs along the spinal canal. Gravity helps the anaesthetic move and spread more predictably within the cerebrospinal fluid and allows for a more controlled and consistent block of the desired nerve roots.

Additionally, the drug is more likely to be distributed evenly across the lower spinal segments, helping to achieve the correct level of anaesthesia, especially in the lower abdomen or legs. This position also provides easy access to the lumbar spine for the procedure and helps the patient remain comfortable and relaxed, reducing the risk of complications such as Post-dural Puncture Headache (PDPH) or nerve injury. A volume of 2.4 mL of 0.5% heavy Bupivacaine was administered, and a T10 level of anaesthesia was achieved [Table/Fig-2a,b].



[Table/Fig-2]: The technique used to administer spinal technique and left lateral position given to the patient.

The patient was stable, and the procedure was initiated [Table/Fig-3]. The procedure was uneventful, and haemostasis was achieved. There was healthy wound recovery. The patient was haemodynamically stable, with non invasive blood pressure, heart rate, and oxygen saturation within normal limits, and was discharged on the 7th postoperative day.



[Table/Fig-3]: Routine intraoperative vitals monitoring.

DISCUSSION

Regional anaesthesia carries less risk compared to general anaesthesia [1,2]. It has been associated with fewer complications and shorter hospital stays in patients undergoing major lower limb or truncal surgeries [3,4]. A lifetime risk of 19-34% has been reported for developing diabetic foot ulcers, with approximately 50-60% of ulcers becoming infected. A total of 20% of these infected wounds result in lower limb amputations [5].

Patients undergoing lower limb amputations need to receive local or regional anaesthesia instead of general anaesthesia, a need that is further increased if the patient is on prolonged anticoagulants [6]. Regional anaesthesia may help reduce respiratory morbidity and postoperative cognitive dysfunction while providing good quality postoperative analgesia. Additionally, it can also result in better haemodynamic stability [7,8].

Research evidence suggests that regional anaesthesia techniques used for lower extremity amputation offer certain advantages, such as early mobilisation, shorter hospital stays, effective postoperative analgesia, lower thromboembolism risk, reduced need for transfusion, and lower costs [9]. Similar observations were noted in present case.

Patients on anticoagulants presenting to the Emergency Department need to be managed with neuraxial anaesthesia, which may carry a risk of vertebral canal haematoma and peripheral nerve blocks [4,10].

Regional anaesthesia might also help avoid perturbations in cardiovascular haemodynamics, augmented stress responses, and hypercoagulability associated with general anaesthesia. The elimination of the need for sedatives and intubation makes regional anaesthesia more physiologic, allowing for a favourable influence on postoperative mortality and morbidity. The use of general anaesthesia could be associated with an increased risk of respiratory failure and sepsis compared to regional anaesthesia [11].

The introduction of ultrasound-guided regional anaesthesia for lower limb amputation has made this procedure more precise. The physiological advantages of regional anaesthesia over general anaesthesia include the maintenance of the body's physiological response to stress, improved stump blood flow, and comparable or superior postoperative analgesia. Avoidance of mechanical ventilation, improved haemodynamics, early functional recovery, and decreased coagulability in patients receiving regional anaesthesia are benefits for reducing postoperative pulmonary complications compared to general anaesthesia during lower extremity amputation [12].

In addition to other risks, venous thromboembolism is an added concern in cardiac patients. The incidence is 1 per 21,643 epidural injections, which might be higher in groups with additional risk factors such as old age, osteoporosis, and peripheral vascular disease. Factors that significantly increase the risk include female gender, age, a history of bleeding and bruising, the continuous catheter method, multiple attempts, and a larger needle gauge [13]. As observed in present case, which presented in the Emergency Department and did not have the time to cease anticoagulants, regional anaesthesia was utilised for the management of lower limb amputation due to gangrene, mitigating the higher risks associated with general anaesthesia. A smaller-gauge needle was utilised, which further helped prevent vertebral haematoma due to the neuraxial block.

The guidelines from the American Society of Regional Anaesthesia (ASRA) and the Association of Anaesthetists (AoA) recommend discontinuing oral anticoagulant drugs two to five days prior to the procedure, a practice that should be observed in all elective surgeries [4,13]. New research initiatives suggest the use of smartphone-based decision support tools that are based on various available guidelines for managing regional anaesthesia in patients on anti-thrombotic therapy [14].

In conclusion, patients with lower extremity amputations who received regional anaesthesia required a shorter stay in the intensive care unit and had shorter overall hospital stays. Additionally, mortality rates were lower in patients operated on under regional anaesthesia compared to those who underwent general anaesthesia. Therefore, based on available evidence and present case, authors recommend this treatment protocol for patients on unadjusted anticoagulants presenting in the emergency department.

CONCLUSION(S)

Anaesthetic management becomes more challenging based on vulnerabilities and requires a delicate balance and precise decision-making predicated on the clinical condition of the patient and the suitability of the technique employed. There is a high risk of spinal haemorrhage and haematoma in patients on anticoagulants undergoing regional anaesthesia for emergency procedures such as lower limb amputations. This risk can be further elevated by the presence of co-morbidities such as diabetes, hypertension, and cardiovascular diseases. The present case highlights the intricacies of managing spinal anaesthesia in patients on anti-thrombotic medications, who require special considerations such as the timing of drug cessation, adjustment of dosages, and monitoring for bleeding complications. For such patients, maintaining haemodynamic stability

during spinal anaesthesia is crucial. The present case report contributes to understanding how spinal anaesthesia affects blood pressure and circulation in patients on anti-thrombotic therapy. Additionally, these cases necessitate close monitoring of coagulation parameters {Prothrombin Time (PT), International Normalised Ratio (INR) and Activated Prothrombin Time (aPTT)} and postoperative haemostasis is important. The present type of case study encourages the refinement of perioperative care protocols, improving patient safety and establishing evidence-based practices for managing high-risk patients undergoing complex and life-saving surgeries.

REFERENCES

- [1] Nakamura M, Kamei M, Bito S, Migita K, Miyata S, Kumagai K, et al. Spinal anaesthesia increases the risk of venous thromboembolism in total arthroplasty: Secondary analysis of a J-PSVT cohort study on anaesthesia. *Medicine* (Baltimore). 2017;96(18):e6748. Doi: 10.1097/MD.0000000000006748.
- [2] Kietaihl S, Ferrandis R, Godier A, Llau J, Lobo C, Macfarlane AJ, et al. Regional anaesthesia in patients on antithrombotic drugs: Joint ESAIC/ESRA guidelines. *Eur J Anaesthesiol*. 2022;39(2):100-32. Doi: 10.1097/EJA.0000000000001600.
- [3] Kiguchi MM, Schobel H, TenEyck E, Earls B, Pan-Chen S, Freedman E, et al. The risks and benefits of early venous thromboembolism prophylaxis after elective spinal surgery: A single-centre experience. *J Perioper Pract*. 2022;32(11):286-94. Doi: 10.1177/17504589211002070.
- [4] Ashken T, West S. Regional anaesthesia in patients at risk of bleeding. *BJA Educ*. 2021;21(3):84-94. Doi: 10.1016/j.bjae.2020.11.004.
- [5] Edmonds M, Manu C, Vas P. The current burden of diabetic foot disease. *J Clin Orthop Trauma*. 2021;17:88-93. Doi: 10.1016/j.jcot.2021.01.017.
- [6] Cappelleri G, Fanelli A. Use of direct oral anticoagulants with regional anaesthesia in orthopedic patients. *J Clin Anaesthesia*. 2016;32:224-35.
- [7] Fraser K, Raju I. Anaesthesia for lower limb revascularization surgery. *BJA Education*. 2015;15(5):225-30.
- [8] Nishiyama T. Anaesthesia for leg amputation in high risk patients. *Int Biol Biomed J*. 2020;6(4).
- [9] Kurt N. Surgical outcomes of regional versus general anaesthesia in 203 patients with upper- and lower-extremity amputation: A retrospective study from a single center in Turkey. *Med Sci Monit*. 2022;28:e938603. Doi: 10.12659/MSM.938603.
- [10] Neal JM, Barrington MJ, Brull R, Hadzic A, Hebl JR, Horlocker TT, et al. The second ASRA practice advisory on neurologic complications associated with regional anaesthesia and pain medicine: Executive Summary 2015. *Reg Anaesth Pain Med*. 2015;40(5):401-30. Doi: 10.1097/AAP.0000000000000286.
- [11] Mufarrih SH, Qureshi NQ, Yunus RA, Katsiampoura A, Quraishi I, Sharkey A, et al. A systematic review and meta-analysis of general versus regional anaesthesia for lower extremity amputation. *J Vasc Surg*. 2023;77(5):1542-52. Doi: 10.1016/j.jvs.2022.10.005.
- [12] Mufarrih SH, Qureshi NQ, Schaefer MS, Sharkey A, Fatima H, Chaudhary O, et al. Regional anaesthesia for lower extremity amputation is associated with reduced post-operative complications compared with general anaesthesia. *Eur J Vasc Endovasc Surg*. 2021;62(3):476-84. Doi: 10.1016/j.ejvs.2021.05.040.
- [13] Benzon HT, Jabri RS, Zundert TC. Neuraxial anaesthesia and peripheral nerve blocks in patients on anticoagulants. *NYSORA Textbook of Regional Anaesthesia and Acute Pain Management*. McGraw Hill. 2007.
- [14] McEvoy MD, Hand WR, Stiegler MP, DiLorenzo AN, Ehrenfeld JM, Moran KR, et al. A smartphone-based decision support tool improves test performance concerning application of the guidelines for managing regional anaesthesia in the patient receiving antithrombotic or thrombolytic therapy. *Anaesthesiol*. 2016;124(1):186-98.

PARTICULARS OF CONTRIBUTORS:

1. Junior Resident, Department of Anaesthesiology, Jawaharlal Nehru Medical College, DMIHER, Sawangi, Meghe, Wardha, Maharashtra, India.
2. Professor and Head, Department of Anaesthesiology, Jawaharlal Nehru Medical College, DMIHER, Sawangi, Meghe, Wardha, Maharashtra, India.

NAME, ADDRESS, E-MAIL ID OF THE CORRESPONDING AUTHOR:

Dr. Prachi Deshmukh,
Junior Resident, Department of Anaesthesiology, Jawaharlal Nehru Medical College,
DMIHER, Sawangi, Meghe, Wardha-442001, Maharashtra, India.
E-mail: prachipdeshmukh@gmail.com

PLAGIARISM CHECKING METHODS: [Jain H et al.]

- Plagiarism X-checker: Jan 13, 2025
- Manual Googling: Mar 08, 2025
- iThenticate Software: Mar 10, 2025 (9%)

ETYMOLOGY: Author Origin

EMENDATIONS: 5

AUTHOR DECLARATION:

- Financial or Other Competing Interests: None
- Was informed consent obtained from the subjects involved in the study? Yes
- For any images presented appropriate consent has been obtained from the subjects. Yes

Date of Submission: Jan 10, 2025

Date of Peer Review: Jan 28, 2025

Date of Acceptance: Mar 12, 2025

Date of Publishing: Apr 01, 2025